

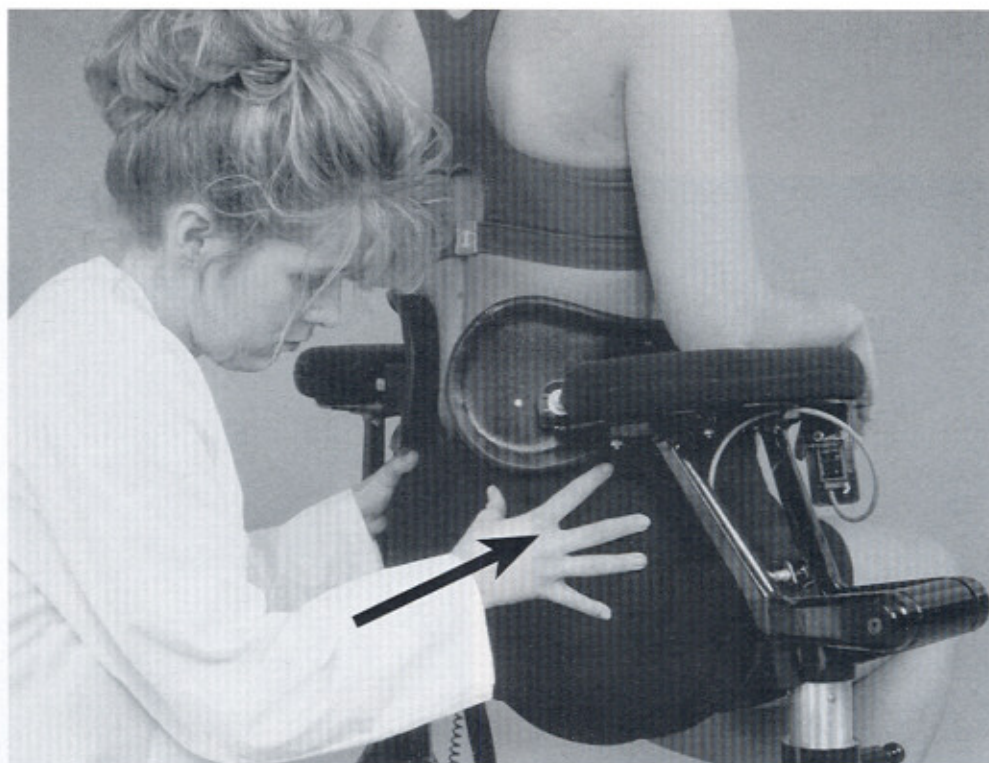

Fig. 7-12 Close-up of clinician performing posterior adjustment on LTX 3000.

- Patient is positioned on the LTX 3000, with traction on the lower back.
 - Clinician is positioned kneeling behind the patient, mobilizing the ilium.
 - This is being performed while the patient is in seated traction, with the spine unloaded.
- (Courtesy Spinal Designs, Minneapolis, Minn.)




Fig. 7-13 See legend opposite page.